

# Pre- and Postoperative Sinus Penetration of Nasal Irrigation

Alethea Grobler, MBBS; Erik K. Weitzel, MD; Achim Buele, MD; Camille Jardeleza, MD;  
Yew C. Cheong, MD; John Field, PhD, AStat; Peter-John Wormald, MD, FRACS

**Objective/Hypothesis:** Endoscopic sinus surgery is an accepted treatment for medically recalcitrant chronic rhinosinusitis. Effective saline douching may improve long-term outcomes of chronic rhinosinusitis but is often impaired by postoperative ostial stenosis. The aim of this study is to determine a critical ostial size at which douching solution reliably enters the sinus cavities.

**Study Design:** Prospective study of consecutive patient cohort.

**Methods:** Seventeen preoperative or well-healed postoperative endoscopic sinus surgery patients were irrigated with 5 mL blue food coloring mixed with 200 mL buffered saline from a squeeze bottle. The degree of sinus penetration, sinus ostial patency, and ostial size were endoscopically determined.

**Results:** Sinuses penetrated by blue dye had a significantly larger minimal ostial dimension (7.31 mm; 95% confidence interval 5.54–9.08) than those that had no blue dye penetration (1.26 mm; 95% confidence interval 0.86–1.66) as determined by Student *t* test. Chi-square analysis showed that operated sinuses were more likely to be penetrated than nonoperated sinuses ( $P = .0016$ ) and obstructed sinuses ( $P = .0325$ ). Logistic regression showed a 95% probability of penetration when the minimum ostial dimension is 3.95 mm or greater.

**Conclusions:** Unoperated sinuses or cases with gross sinus ostial obstruction will not be reliably penetrated by sinus irrigant. A 3.95-mm ostial diameter seems to be the minimum size to guarantee penetration in paranasal sinuses to maximize the potential for topical sinus treatment.

**Key Words:** Endoscopic sinus surgery, nasal irrigation, sinus ostia stenosis, nasal douche.

*Laryngoscope*, 118:●●–●●, 2008

## INTRODUCTION

There is a growing interest in topical treatments of sinus mucosa to improve healing and treat recalcitrant sinus infections especially in the postoperative period. There may also be a role for topical treatments for patients with chronic rhinosinusitis. However, a careful review of the literature shows that existing nasal delivery techniques do not consistently penetrate the paranasal sinuses in both the preoperative and postoperative setting.<sup>1–3</sup> In fact, current experimentation has not established any basic physical constraints for reliable sinus penetration. Establishment of a good understanding of the constraints necessary to predict sinus penetration from a nasal delivery system is a necessary preliminary step before experimenting with topical sinus treatments.

The aim of this study is to determine the physical requirements necessary for delivery of nasal douching irrigant into the paranasal sinuses. Establishing this principle has wider implications for determining critical constraints to predict a method of reliable topical medical treatment to the paranasal sinuses.

## METHODS

A total of 17 patients were included in the study. Patients were excluded if they were unable to perform douching because of mobility or musculoskeletal limitations. After obtaining informed consent, patients were observed while douching both nostrils with a total of 150 to 200 mL of irrigant just before functional endoscopic sinus surgery or at greater than 3 months postoperative follow up. A 200-mL commercially available plastic squeeze bottle (NeilMed Pharmaceuticals, Australia) was used for irrigation while the patient leaned over a sink placing the forehead in a dependent position. The irrigant consisted of 200 mL water, 5 mL blue food coloring (Queen Essence Food Colors, Australia), and a packet of NeilMed buffered saline salt mixture. A similar technique was previously described and found to be effective for identifying sinus penetration of irrigant.<sup>4</sup> No decongestant medication was used before douching as this may have altered the penetration pattern.

A standardized video-endoscopy<sup>5–8</sup> was then performed after the induction of general anesthesia (preoperative patients) or after topical administration of Cophenylcaine forte spray (ENT Technology, Australia) in the postoperative group to search for the presence of blue dye in each sinus. The presence of blue dye, regardless of the extent of staining, was recorded as a penetrated

From the Department of Surgery–Otolaryngology, Head and Neck Surgery, University of Adelaide and Flinders University, The Queen Elizabeth Hospital, Woodville, South Australia, Australia.

Editor's Note: This Manuscript was accepted for publication June 3, 2008.

Peter-John Wormald has a financial interest/arrangement with Medtronic Xomed for royalties received from the design of surgical instruments.

Send correspondence to Peter-John Wormald, MD, 28 Woodville Road, Woodville, South Australia 5011, Australia. E-mail: peterj.wormald@adelaide.edu.au

DOI: 10.1097/MLG.0b013e31818208c1

sinus. Expert rhinologists measured minimum and maximal ostial size dimensions using an instrument of known tip size as a measuring device. The minimum ostial dimension was judged to be the smaller of the two measurements used in determining the ostial size. Additionally, intranasal obstructions that would prevent irrigant from reaching the ostia were noted including massive polyps, large synechiae, or severe turbinate lateralization. Thereafter, routine endoscopic sinus surgery was performed and any dye noted in sinus cavities during the procedure was recorded. The surgical ostial enlargement permitted intrasinus visualization in the cases when ostia were smaller than the tip of the endoscope (<4 mm). The surgical procedure was not influenced or altered by participation in the trial.

Statistical analysis was performed using the R statistical language [R Development Core Team (2007). R: A language and environment for statistical computing. R Foundation for Statistical Computing, Vienna, Austria. ISBN 3-900051-07-0, URL <http://www.R-project.org>]. Logistic regression was used in nonobstructed ostial data to predict penetration at specified ostial dimensions. Student *t*-test was used to compare the penetrated and nonpenetrated groups for significant dimension differences. Chi-square analysis was used to detect significant differences in penetration between the preoperative, obstructed, and postoperative groups.

## RESULTS

A total of 75 ostia and sinuses were analyzed establishing the power at 0.988 given an alpha of 0.05. Those sinuses that were penetrated by blue dye had a significantly larger ostial area (maximum × minimum dimensions) than those that weren't penetrated (96.81 mm<sup>2</sup>; 95% CI 57.12–136.5 vs. 2.85 mm<sup>2</sup>; 95% CI 1.54–4.16; *P* < .001). The minimum ostial dimension showed a similar relationship (7.31 mm; 95% CI 5.54–9.08 vs. 1.26 mm; 95% CI 0.86–1.66; *P* < .0001) (Fig. 1). For the maxillary sinus alone, a mean minimum dimension of 9.2 mm (95% CI 7.54–12.46) was seen in sinuses penetrated by irrigant

whereas a mean minimum of 1.9 mm (95% CI 0.32–4.924) was seen in the unpenetrated sinuses (*P* = .0174). The dimension for the frontal sinus was 3.6 mm (95% CI 2.504–4.496) vs. 0.7 mm (95% CI –0.650–1.650) (*P* < .0001) and the sphenoid sinus was 4.7 mm (95% CI 3.022–6.644) vs. 1.31 mm (95% CI –0.32–3.034) (*P* = .0038).

By chi-square analysis, operated ostia were more likely to be penetrated than preoperative unobstructed (Pearson  $\chi^2$  12.01, *P* = .0016) and obstructed ostia (Pearson  $\chi^2$  4.57, *P* = .0325). Likewise, preoperative unobstructed (classified as “Normal”) ostia were more likely to be penetrated than obstructed ostia (Pearson  $\chi^2$  29.67, *P* < .0001) (Fig. 2).

From the logistic regression, a predicted probability of 95% for irrigant penetration of sinus ostia is attained when the minimum dimension is 3.95 mm (Fig. 3).

Logistic regression was also performed for maxillary, frontal, and sphenoid sinuses individually. For the sphenoid sinus, a minimum dimension of 4.84 mm has 95% probability of penetration, but there were no statistically significant regression results for the maxillary and frontal ostia individually.

## DISCUSSION

Our results suggest that there is a critical sinus ostial dimension of 3.95 mm that would guarantee irrigant penetration in at least 95% of cases. Increasing the sinus dimension will in turn increase the likelihood of penetration even further. Below this dimension, penetration diminishes in a characteristic logistic regression fit. This is true for all the sinuses, although the sphenoid sinus minimum ostial dimension is slightly larger, likely due to its anatomical position in the paranasal sinuses and the effect of gravity during douching. A larger sample size may

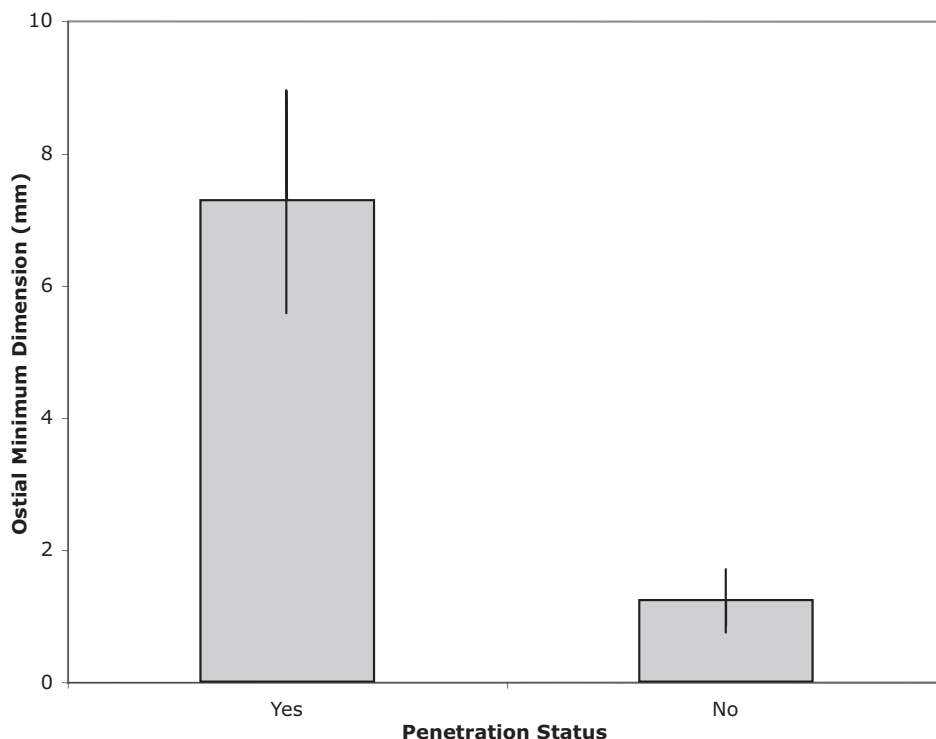


Fig. 1. Minimal ostial dimension (in mm) is noted to be significantly larger in those sinuses that were penetrated. The y-error bars represent 95% confidence intervals.

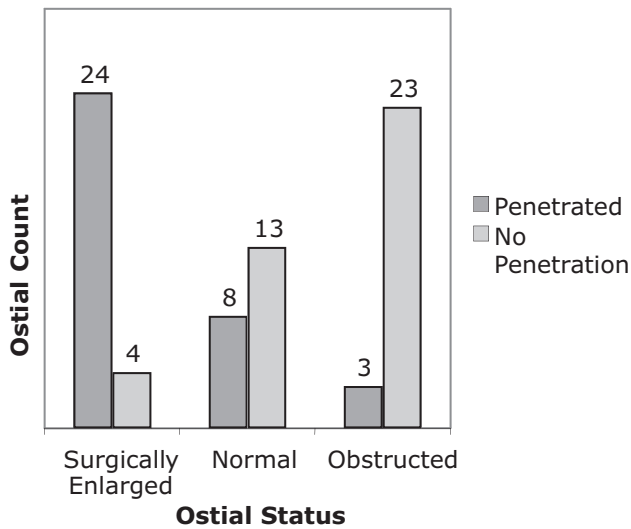


Fig. 2. Frequency histogram of penetration grouped by ostial status. Preoperative ostia were classified as either "Normal" if unobstructed or "Obstructed." Surgically enlarged ostia were frequently penetrated whereas the normal and obstructed ostia were much less likely to be penetrated.

allow predictions to be made for each individual sinus, with 3.95 mm being the overall critical dimension. Postoperative sinuses have greater penetration of irrigant secondary to surgical ostial enlargement whereas obstructed sinuses have less chance of successful irrigant

penetration. Although this has been suggested in modeling experiments,<sup>9</sup> the results have never been verified in humans. It is possible that the 3.95 mm dimension is the smallest that would overcome surface tension of buffered saline, but further studies are required to confirm this finding.

Our results indicate that obvious intranasal obstructions that would prevent irrigant from reaching an ostium are associated with poor penetration regardless of ostium size. The obstruction status was predicted before the results were collected, thus it was the surgeon's impression that suggested a blockage, be it a polyp, severe synechiae, or a lateralized turbinate, would prevent blue dye from penetrating. Our statistics suggest that the surgeon's opinion was usually valid (88%, n = 26).

Irrigation of the nasal cavity and sinuses has been widely accepted as part of the treatment of chronic rhinosinusitis and also in the postoperative period to remove blood clots and mucus from the sinus and nasal cavities. One of the aims of endoscopic sinus surgery is to enlarge the natural sinus ostia and remove obstruction to allow adequate ventilation and drainage of the diseased sinuses. Irrigation of the sinuses and the new sinus ostia is thought to be beneficial for healing and prevention of scarring and adhesions after surgery and many techniques have been described.<sup>1-4</sup> Most authors state that douching of the nose is more effective than nasal sprays or nebulized medications,<sup>1,4</sup> but there is no literature on the effectiveness of nasal douching in particular on the penetration of sinuses before and after surgery. These douches

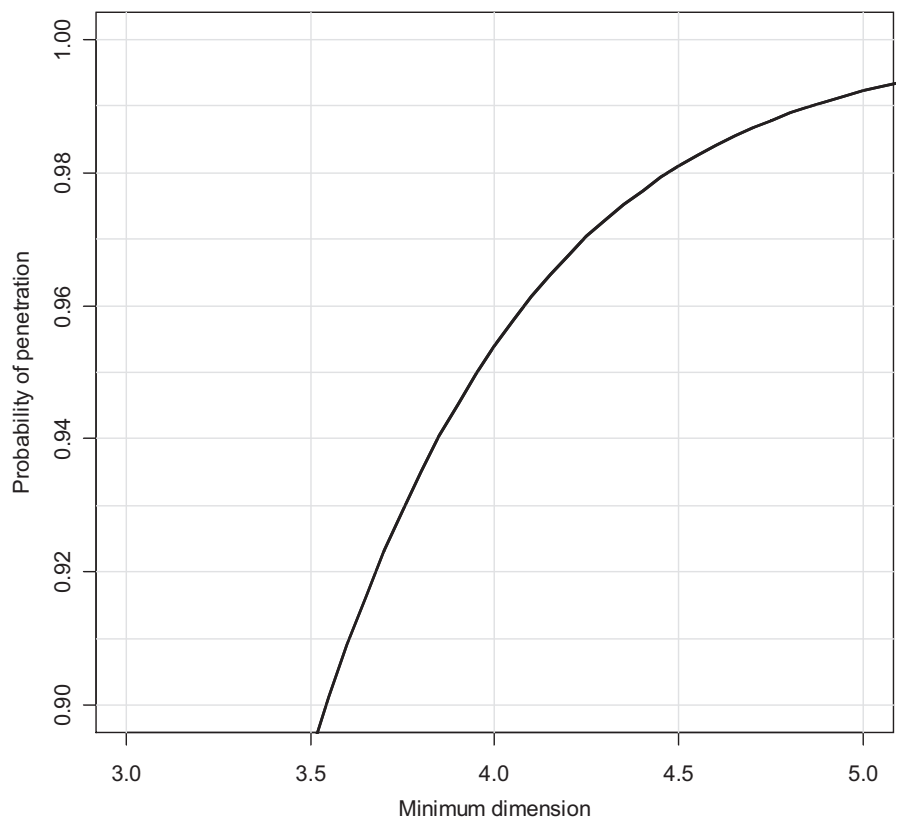


Fig. 3. Minimum ostial dimension of sinus ostia (mm) is shown on the x-axis. The probability of sinus penetration by irrigant shown on the y-axis is determined by logistic regression. A probability of penetration of 0.95 corresponds to a minimum dimension of 3.95 mm. Only nonobstructed ostia were used in determination of this figure.

may contain corticosteroids, antihistamines, or antibiotic medications but effectivity is dependant on sinus and ostial penetration of these solutions.<sup>4,10,11</sup>

## CONCLUSION

Intranasal irrigation is effective at penetrating non-obstructed sinuses with a minimum ostial dimension of 3.95 mm.

## BIBLIOGRAPHY

1. Wormald PJ, Cain T, Oates L, Hawke L, Wong I. A comparative study of three methods of nasal irrigation. *Laryngoscope* 2004;114:2224–2227.
2. Lebowitz RA, Doud Galli SK. Effective application of nasal steroids spray in common practice. *Op Tech Otolaryngol Head Neck Surg* 2001;12:112–114.
3. Cannady SB, Batra PS, Citardi MJ, Lanza DC. Comparison of delivery of topical medications to the paranasal sinuses via “vertex-to-floor” position and atomizer spray after FESS. *Otolaryngol Head Neck Surg* 2005;133:735–740.
4. Miller TR, Muntz HR, Gilbert ME, et al. Comparison of topical medication delivery systems after sinus surgery. *Laryngoscope* 2004;114:201–204.
5. Yanagisawa E. The use of video in ENT endoscopy: its value in teaching. *Ear Nose Throat J* 1994;73:754–763.
6. Yanagisawa E, Walker RK, Alberti PW. Telescopic videorhinology: a useful addition to the clinical practice of rhinology. *Laryngoscope* 1986;96:1231–1235.
7. Yanagisawa E, Christmas DA. The value of computer-aided (image-guided) systems for endoscopic sinus surgery. *Ear Nose Throat J* 1999;78:822–824, 826.
8. Athanasiadis T, Beule A, Embate J, et al. Standardised videoendoscopy and surgical field grading scale for endoscopic sinus surgery: a multi-centre study. *Laryngoscope*. 2008; 118:314–319.
9. Durand M, Rusch P, Granjon D, et al. Preliminary study of the deposition of aerosol in the maxillary sinuses using a plastinated model. *J Aerosol Med* 2001;14:83–93.
10. Homer JJ, Raine CH. An endoscopic photographic comparison of nasal drug delivery by aqueous spray. *Clin Otolaryngol* 1998;23:560–563.
11. Tsikoudas A, Homer JJ. The delivery of topical nasal sprays to the middle meatus: a semiquantitative analysis. *Clin Otolaryngol* 2001;26:294–297.