

Irish Medical Times

Allergic rhinitis: new insights, new therapies Dr Paul Carson

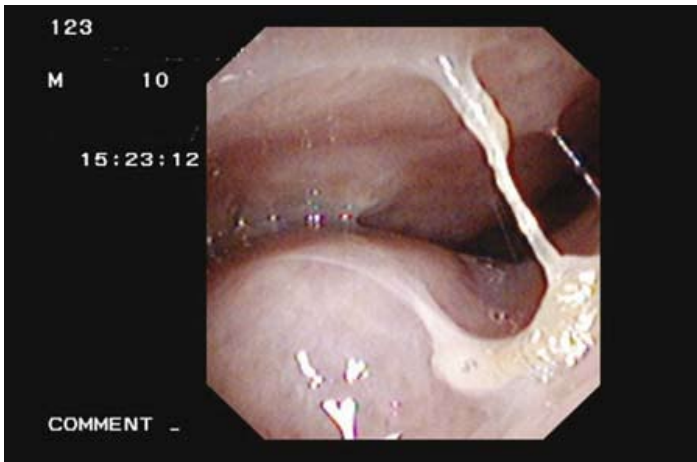


Image 1: Note the degree of turbinate swelling with mucosal apposition, sub-mucosal oedema and copious discharge.

Dr Paul Carson on how his investment in fibre optic technology has provided some new perspectives on allergic rhinitis and the importance of managing the condition.

At the risk of boring you about a topic many dismiss as trivial, may I persuade you to re-think your notions on allergic rhinitis? Why? Because allergic rhinosinusitis is far from unimportant and indeed is the gateway to asthma and possibly other conditions such as serous otitis media and nasal polyps.

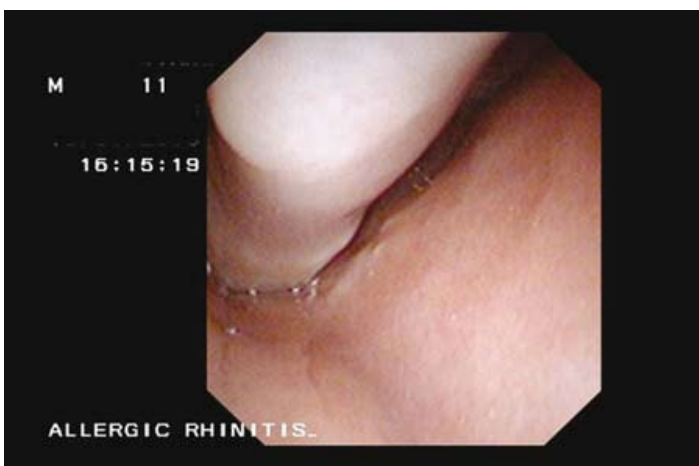


Image 2: Note turbinate swollen along its full length, tapering to cause total obstruction at the top of the nose. Note also pale blue colour, seen only in chronic untreated allergic rhinitis.

Treatments are largely based on how symptomatic the patient (i.e. how loud does he/she protest?), direct

inspection of the immediate nasal cavity and whatever therapy you feel suits the overall picture.

Certainly some sinus patients have such a bizarre range of complaints they are often rushed out the door. But perhaps their misery is not exaggerated; maybe their discomfort matches exactly the clinical findings. Let me explain further.

About 15 years ago, I invested in a fibre optic for assessment of the upper airways. At the time, I considered it a wonderful tool and described its usefulness as finally opening a door that had been firmly shut for years.

A whole range of pathology became obvious in the nose, sinuses and post nasal space. The larynx and vocal cords could be inspected in real time and I became the first GP in the world to identify the (supposedly) rare condition paradoxical vocal cord spasm masquerading as asthma (report published in Irish Medical Journal).

h4. Fast forward

Fast forward to 2008 and now I have re-invested in the latest upper-airways fibre optic technology (Olympus ENF type V2 fiberscope), which gives even clearer images that can be observed on LCD screen, printed as a colour image for the patient and saved to a computer.

This is the smallest ever upper airways scope with diameter of 3mms, allowing a relatively painless inspection of the nasal cavity, post nasal space, pharynx and larynx. The images it produces are dramatic in clarity and colour and allows pathology to be observed directly and simultaneously recorded. This has forced me to re-think my management of rhinitis/sinusitis patients, based on what is observed through the scope:

- 1) The degree of nasal mucosal swelling is much worse than can be assessed by direct visual inspection of the nasal cavity (image 1).
- 2) The amount of oedema of the nasal turbinates is such that there has to be (I believe) a systemic component to what I had always assumed was a topical, or surface problem (images 3 and 1).
- 3) The degree of obstruction must create significant clinical symptoms (image 2).
- 4) The amount of copious post nasal drip cannot be explained by the usual descriptions in ENT textbooks (image 3).

5) The whole picture of allergic rhinitis, if it offers us a mirror to what is going on in the lungs in asthma, should force a re-think on management of both conditions.

Let's get to the points of management:

1) Most rhinitis/sinusitis patients self medicate before they attend the family doctor for help.

2) Most rhinitis/sinusitis patients will have had an array of over the counter (OTC) and prescribed medications before they reach the ENT specialists.

3) Most rhinitis/sinusitis patients will be offered variations on the same theme of both OTC and prescribed therapies by the ENT specialist unless there is a surgical option.

4) Most rhinitis/sinusitis patients continue to suffer a significant degree of chronic discomfort despite medical and/or surgical intervention.

What should be done?

1) Listen to the patient.

2) If the patient is a child, remember that he/she may not be able to vocalise complaints (indeed unwellness may present as grumpiness and irritability).

3) Always inspect the nasal cavity.

4) Always pre-treat with intra-nasal steroid drops to restore the nasal cavity to some degree of normality, especially to reduce mucosal swelling and oedema.

5) Only introduce an intra-nasal steroid when you feel the nose is patent enough to 'accept' the spray.

6) Consider oral anti-histamines and nasal steroids during acute allergic challenge times such as hay-fever season.

7) Consider anti-leukotriene agents and nasal steroid where there is combined upper and lower airway symptoms.

8) Add in an anti-leukotriene agent to the maintenance nasal steroid where the nasal obstruction/oedema is stubborn to clear.

9) Consider nasal douching as an additional maintenance therapy (there is an excellent OTC product called **NeilMed Sinus Rinse**, no more than salt and sodium bicarbonate granules that dissolve in 120mls of water and is squirted up each nostril in turn to cleanse and refresh the usually swollen, irritable mucosa). This product is a real winner for those patients unwilling to continue standard therapy because of steroid-phobia. As I explain to patients, **NeilMed Sinus Rinse** can do no harm (when used correctly), is available without prescription and has toll-free numbers to call for advice about the rinse and its use. As a nasal douche, its ability to reach the upper nostrils by far makes it superior to rival products.

10) When you have reversed your patient's discomfort

and identified the allergic trigger, give sub-lingual immunotherapy (e.g. Grazax in pollen hay fever) serious consideration as it may produce a cure rather than the lifelong control that is pushed so hard.

Important points:

Allergic rhinitis may extend into the sinuses (rhinosinusitis).

Allergic rhinitis may cause upper airway symptoms only.

Allergic rhinitis may provoke lower airways symptoms.

Allergic rhinitis may co-exist with asthma.

Allergic rhinitis (untreated) may allow nasal polyps to develop.

Allergic rhinitis can also cause such diverse symptoms as sleep apnoea and other sleep disturbances, chronic mouth breathing (with resulting facial bone mal-development in children), reduced sense of smell and taste, exercise-induced asthma, fatigue and nausea (usually from swallowing copious post nasal drip material).

Finally, concomitant allergic rhinitis in asthmatic children is associated with an increased likelihood of asthma-related hospital re-admissions and greater total days spent in hospital (Sazonov et al. 'Association between allergic rhinitis and hospital resource use among asthmatic children in Norway'. *Allergy*.2005,60:338-342.).

Dr Paul Carson is a member of the British Society for Allergy & Clinical Immunology, the European Academy of Allergology and Clinical Immunology and on the board of the Irish Lung Foundation. He runs the Allergy Investigation, Diagnosis and Treatment facility at Slievemore Clinic, Dublin. (www.allergy-ireland.ie)

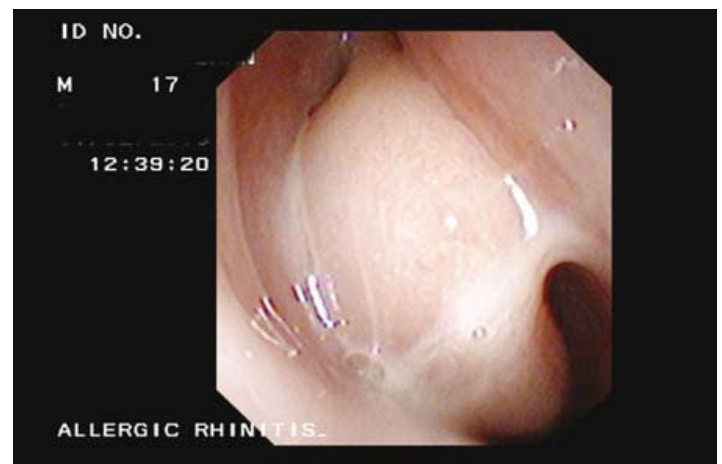


Image 3: Note gross turbinate swelling with total nasal obstruction; marked sub-mucosal oedema and copious nasal discharge that was observed also in post-nasal space.